


Spring 5-1-2017

Beyond Capture: Development and Validation of a Method to Assess Body Condition in Mule Deer (*Odocoileus hemionus*) Using Camera Traps

Rachel A. Smiley 6820420
rachel.smiley@uconn.edu

Follow this and additional works at: http://digitalcommons.uconn.edu/srhonors_theses

 Part of the [Environmental Health Commons](#), [Other Nutrition Commons](#), and the [Zoology Commons](#)

Recommended Citation

Smiley, Rachel A. 6820420, "Beyond Capture: Development and Validation of a Method to Assess Body Condition in Mule Deer (*Odocoileus hemionus*) Using Camera Traps" (2017). *Honors Scholar Theses*. 533.
http://digitalcommons.uconn.edu/srhonors_theses/533

Beyond capture: development and validation of a method to assess body condition in mule deer (*Odocoileus hemionus*) using camera traps

Rachel A. Smiley
Department of Natural Resources and the Environment
University of Connecticut
Spring 2017

Submitted in Fulfillment of University Scholar and Honors Program Requirements

ABSTRACT

Advances in technology and availability associated with camera traps have resulted in a rapid rise in their use to monitor wildlife distribution, abundance, and behavior. We focus on assessing body condition, a new application of camera traps. Body condition indices must relate to the percent body fat if they are to be useful. To acquire measurements of body fat, most body condition indices require capture or mortality of animals to estimate, which has limitations when applied to free-ranging animals. We developed a non-invasive, visual body condition index (VBCI) to assess body condition of mule deer that can be applied to camera trap images or videos. The VBCI was based on the visibility of five bone regions, the scapula, spinal ridge, ribs, tuber ischium, and tuber ilium, which are covered in varying amounts of subcutaneous fat. We compared the VBCI to known values of ingesta-free body fat, obtained from ultrasonography and physical palpation of captured mule deer. Our VBCI was positively related to percent ingesta-free body fat ($R^2=0.23$, $p<0.001$). Additionally, the bone regions evaluated were each correlated with the percent ingesta-free body fat. Using Spearman's correlation, the scapula is the region most highly correlated to ingesta-free body fat (0.44, $p<0.001$), followed by the ischium (0.36, $p<0.001$), ilium (0.35, $p<0.001$), spinal ridge (0.31, $p<0.001$), and ribcage (0.12, $p<0.01$). Based on the relationships between VBCI and ingesta-free body fat, we developed two visual body condition indices, one that requires a broadside orientation to the camera (VBCI-1) and one that is applicable when a deer is quartered towards the camera (VBCI-2). Potential applications of the VBCI include evaluating relationships between body condition and habitat enhancements, habitat disturbances, population performances, and weather.

INTRODUCTION

Advances in camera trapping technology and improved availability have resulted in the rapid increase in camera trap usage (O'Connell et al. 2011). The less-invasive nature of camera trapping methods has led to the detection of species sensitive to human disturbances (Kucera and Barrett, 2011). Camera trapping has gained popularity for evaluating wildlife distribution, abundance, and behavior (Burton et al. 2015), particularly for rare and cryptic species. However, the range of camera trapping application is also expanding (Newey et al. 2015), and there is considerable potential for camera trapping to aid in understanding the ecology and subsequent management of relatively common and well-studied species.

One new application of camera traps is the development and application of body condition indices. Understanding the body condition of individuals provides information that is useful for management of a population. Body condition indices are valuable management tools that presume the physical condition of an individual directly influences its reproduction success and survival. In mammals, fat content is very closely related to the condition, health, and reproductive potential of adult females (Gerhart et al. 1996). Subcutaneous fat is strongly associated with total body fat and gross energy (Cook et al. 2001) and strong links exist between nutrition, maternal body condition and offspring survival (Monteith et al. 2014). There is a high correlation between body fat content and body condition scores for various mammal species (Cook et al. 2001). Yet, most indices require capturing live animals and measuring body condition through ultrasound, hand palpation, blood work, or gathering body condition information from dead animals. Many of the indices also require highly specialized training to attain

consistency among observers, extensive handling of the deer, or a dead deer. For example, rumpBCS, involves palpation of the deer rump to estimate fat content (Wright and Russell 1984, Gerhart et al. 1996, Cook et al. 2001). The MAXFAT index measures the thickness of subcutaneous rump fat using ultrasound (Stephenson et al. 1998; Cook et al. 2001). rLIVINDEX is an index that combines ultrasound measurements of subcutaneous rump fat and rumpBCS (Cook et al. 2007). The MAXFAT index and rLIVINDEX both require specialized training to accurately measure subcutaneous fat thickness using ultrasound (Cook et al. 2007). The Kistner index evaluates body condition in mule deer carcasses using weights and measurements of body organs (Kistner et al. 1980). The Kistner index requires mortality of the animal. These methods of acquiring body condition data are not widely applicable due to their invasive nature, equipment costs, or specialized training requirements.

Visual body condition indices offer a non-invasive alternative that also compliments the passive survey approach of camera trapping methods. Non-invasive, visual body condition indices have been developed for some large mammals, including Baird's tapirs (Perez-Flores et al. 2016) and African elephants (Morfeld et al. 2014). A non-invasive visual body condition index for deer exists which evaluates nutritional condition based on visibility and angle of the tail, pelvic girdle, tuber ilium, the lateral process of the backbone vertebrae, and the ribs (Figure 1; Riney 1960). Riney noted that although there is some subjectivity in scoring ocularly, the method was valid for deer in different habitats (Riney 1982). Although the Riney index is used to estimate deer body condition, this index has not been tested for its relationship with body fat or other body condition indicators, so it is not used widely as a reliable index of body condition.

Riney's visual body condition index is not applicable to camera trap images or videos because the body regions used are too small to be visible, especially in the winter when the deer have thicker coats.

The goal of our study was to develop a non-invasive, visual body condition index for adult female mule deer, with the intent of application to images and videos obtained from camera traps used for management. We sought to develop a method that is statistically validated against known body condition data. Mule deer are considered culturally and economically significant throughout their range (Copeland et al. 2014). Particular interest is taken in their management because populations are facing declines due to a variety of factors including development and habitat loss, predation, weather conditions, and disease. Nutrition and weather are the primary factors that influence population dynamics in mule deer (Forrester and Wittmer, 2013). To obtain nutritional and energetic requirements for survival, many populations of mule deer migrate between low-elevation winter ranges and high-elevation summer ranges, which provide access to high-quality forage needed for successful breeding and recruitment of young (Cook et al. 2004). However, disturbances to these migrations affect their ability to obtain nutritional requirements (Sawyer et al. 2009). One primary disturbance to migration is intensive development, which causes mule deer to change migration routes, increasing rates of movement and decreasing stopover use (Sawyer et al. 2012), and therefore compromising their ability to obtain nutritional requirements. Disturbances in the form of human development, including residential and energy development are linked to decreasing recruitment rates in mule deer (Johnson et al. 2017). Management currently focuses on minimizing these disturbances to migration and improving habitat. Habitat management

to improve nutritional availability can positively influence vital rates in mule deer (Bergman et al. 2014). A non-invasive method for assessing body condition will allow managers to efficiently look at changes in body condition at a population level., which could have implications on evaluating differences in habitat quality, or indicate reasons for low reproductive rates.

METHODS

VBCI Development

We developed a VBCI for adult female mule deer based on the level of visibility of five bone regions. We used the scapula, rib cage, spinal ridge, tuber ischium, and tuber ilium to evaluate the overall body condition of the deer because of the potential visibility of these regions in pictures from various body angles. Theoretically, a bone region covered by minimal subcutaneous fat is visible underneath the skin, a bone region covered by a small amount of subcutaneous fat is partially visible, and a bone region covered by sufficient subcutaneous fat is not visible.

Each region on the deer is scored individually, and the scores for the five regions are together to determine a total score. Regions are scored a 0 if bones are clearly visible on the deer, 0.5 if they are partially visible, and 1 if they are not at all visible on the deer (Figure 2). VBCI scores range from 0 to 5, with 0 indicating a deer with minimal body fat and 5 indicating a deer with high levels of subcutaneous fat. A deer that scores a 0 on the VBCI has very little subcutaneous fat and is considered in poor condition. A deer with a score of 5 has subcutaneous fat in all regions and is considered in optimal condition

because of the positive relationship between amount of body fat and survival and reproductive rates (Gerhart et al. 1996, Cook et al. 2001).

VBCI Validation

To validate a visual body condition index, it is necessary to compare index scores to actual levels of fat within the body. Obtaining measurements of fat within the body requires capturing the animals and evaluating body condition using existing methods. Due to the nature of capture, the deer were agitated, and ran unpredictably after their release, so it was necessary to use a handheld video camera to ensure we would capture visual data to score using the Visual Body Condition Index (VBCI).

We captured mule deer from two herds during December 2015 and March 2016 using hand-held net guns deployed from helicopters throughout western Wyoming ranging from Rock Springs to Jackson, Wyoming. We immediately hobbled and blindfolded the deer, then transferred them to a central processing station. We took biological and morphological measurements, including measuring the percent ingesta-free body fat. During their release, we recorded videos of the mule deer does and fawns using a SONY CX405 Flash Memory Camcorder. We used these videos to score the mule deer using the VBCI.

Using ultrasonography, we measured the maximum thickness of the subcutaneous rump fat cranial to the tuber ischium (Monteith et al. 2014) for all of the adult does captured. Measurements of subcutaneous fat thickness were paired with a physical palpation evaluation to determine a body-condition score (Cook et al. 2007). The body-condition score, body mass, and maximum thickness of subcutaneous rump fat were combined to estimate the percent of ingesta-free body fat according to methods described

by Cook et al. (2010). If the body mass was not available, measurements of chest girth were used to estimate body mass in the ingesta-free body fat calculations (Cook et al. 2010). This study was exempted by University of Connecticut's International Animal Care and Use Committee (IACUC E15- 012) since all approvals and permits were held by cooperators in Wyoming Game and Fish Department (Tony Mong), University of Wyoming (Kevin Monteith), and the U.S. Geological Survey Cooperative Wyoming Fish and Wildlife Research Unit (Matthew Kauffman).

Five observers viewed the release videos of the deer and assigned VBCI scores to the bone regions of each deer and added each bone region score for a total score. One scorer was a volunteer with no prior experience with mule deer or body condition scoring and considered a 'novice'. Two of the observers, also considered 'novices' because of their lack of formal experience with mule deer and body condition scoring, are the authors of this paper and developers of the VBCI (RS, CR). The remaining two observers, considered 'experts' are professionals who regularly work with the mule deer populations studied, including one coauthor of this paper (TM).

All five observers were given the same written instructions on scoring the videos, which included Figure 2 as the primary example of how to score the body regions. All observers were instructed to not provide a score for any body region that was not in view of the camera. Any deer deemed not scorable by any of the observers was not included in the analysis. Reasons that a video may not be scorable included the angle of the deer, video quality, coat condition, or speed the deer was moving.

To evaluate the accuracy of the VBCI, we compared the VBCI scores to the percent ingesta-free body fat, a reliable calculation of mule deer body condition that is

used to validate other body condition indices (Cook et al. 2007). We averaged the scores assigned to each deer across observers and fit a linear model to evaluate the relationship between average VBCI score and estimated percent ingesta-free body fat. We used Spearman's correlations to evaluate the strength of the relationship between the percent ingesta-free body fat and VBCI scores averaged across observers for each region. To evaluate agreement across observers, we determined the percent agreement of total scores between observers using the equation $\frac{100 \times m}{n}$, where m is the number of videos in which both observers agreed upon the total score and n is the total number of videos scored.

When using camera traps, the body angle of the deer relative to the camera affects the visibility of different body regions. Depending on camera placement, full broadside images of deer are more difficult to obtain than images of the deer that are quartered to the camera. In this case, the scapula, rib cage, spinal ridge, and tuber ilium are all visible, but the tuber ischium is not. We fit an additional model to increase the number of scorable videos. The first index (VBCI-1) includes all five regions: the scapula, rib cage, spinal ridge, tuber ilium, and tuber ischium. The second index (VBCI-2) excludes the tuber ischium. The maximum total score using VBCI-2 is 4, because only 4 body regions are scored.

Observers first scored the inverse of the method described, so if a bone region was not visible it received a score of 0 and if it was visible it received a score of 1. Because a higher percent IFBF value indicates better nutritional condition, we inverted the scores during analysis to result in a positive relationship between VBCI score and percent ingesta-free body fat.

RESULTS

Of the 85 release videos obtained, all observers scored 66 adult female mule deer. Scorers considered videos not suitable for scoring due to poor visibility of body regions, usually due to orientation, coat condition, or the speed the deer were moving. In the scored videos, 10 deer were captured and videoed in December, 56 of the deer were captured and videoed in March. Fewer videos were scorable in December than in March because the video quality was poor.

We found a positive relationship between average (across observers) visual body condition score and percent ingesta-free body fat when all five regions were included ($R^2 = 0.23$, $p < 0.001$). As the average VBCI-1 score increased the percent ingesta-free body fat increased (Figure 3). The model that excluded the tuber ischium from the total VBCI score also indicated a positive relationship between VBCI-2 score and percent ingesta-free body fat ($R^2 = 0.22$, $p < 0.001$). VBCI-1, which includes all five body regions, and VBCI-2, which excludes the tuber ischium, are strongly correlated with each other ($R^2 = .97$). Using Spearman's correlation to evaluate VBCI-1, the scapula is the region most highly correlated to IFBF (0.44), followed by the ischium (0.36), ilium (0.35), and spinal ridge (0.31) (Table 1). The ribcage is the least correlated with ingesta-free body fat (0.12) (Table 1).

There was some variation in scoring between observers. Three observers were classified as 'novices', meaning they did not have any formal experience with mule deer or evaluating body condition. Two of the observers were considered 'expert' because of their professional experience working with mule deer and knowledge about body condition. When using VBCI-1, the novice observers all scored the most similarly, with

agreements of 57.35%, 64.71%, and 80.88% (Table 2). The expert observers agreed on 7.35% of the scores (Table 2). Agreement percentage was low when comparing the novice observers to the expert observers.

DISCUSSION

A significant, positive relationship between VBCI score and ingesta-free body fat indicates that the VBCI is a valid method for assessing body condition in mule deer. This supports that subcutaneous fat levels can be evaluated visually and reflect actual measurements of body fat. VBCI scores increased as subcutaneous fat increased, in agreement with other body condition indices.

We developed a visual body condition index validated against actual measures of body fat in free-ranging mule deer. The VBCI score is determined using the visibility of five bone regions. The VBCI ranges from 0, meaning the least amount of fat, to 5 meaning sufficient body fat. Figure 2 demonstrates the varying visibility of the bone regions. We modeled two VBCIs to increase the number of images or videos that are potentially scorable. In situations where camera angle limited the ability to see the tuber ischium, a simplified, 4-region VBCI (VBCI-2) provided similar results to the full VBCI (VBCI-1). The VBCIs both have a strong relationship with ingesta-free body fat in mule deer. The VBCIs are only applicable to images or videos of deer that are broadside or quartered to the camera and close enough and with high enough resolution that bone points could feasibly be visible.

We intend the VBCIs to be applied to camera trap images as well as videos. We used a handheld camera to record videos to facilitate the validation of the VBCI scores

against actual measures of fat taken from free-ranging mule deer, which required capture and physical immobilization, leading to unpredictable behavior upon release. This was a necessary step to move the utility of the VBCI beyond capture. We expect that scoring will be easier and more accurate if images or videos are obtained from camera traps, in which the deer are usually still or walking. Variation in scoring likely resulted from low quality videos, ‘ruffling’ of the deer’s coat during to handling, or orientation of the deer. These sources of variation will not likely be relevant if the VBCI is applied to camera trap images or videos because handling of the deer is not involved.

The VBCIs are simple enough that observers of varying experience levels can accurately identify the visibility of the five bone regions on a deer. Five different observers scored the deer and their average scores are positively correlated to the percent ingesta-free body fat. Observers with a large range of experience with body condition indices, mule deer, and anatomy can use the VBCI effectively. Use of the VBCI does not require extensive training or knowledge base, making it an easily applied method to evaluate nutritional condition in mule deer. When applying the VBCIs, averaging scores from multiple observers will likely improve results.

We found a strong relationship between the five body regions used in VBCI-1 and ingesta-free body fat, similar to other studies. Cook et al. (2007) compared several mule deer body condition indices with percent ingesta-free body fat. We found the scapula is the body region most correlated with the percent ingesta-free body fat, followed by the ischium and ilium (Table 1). The ribcage is the region least strongly correlated with the percent IFBF (Table 1). Subcutaneous fat deposition occurs first in the rump, then across the upper ribs to the withers, then ventrally over the ribs and across the brisket as ingesta-

free body fat increases (Cook et al. 2010). Because the scapula is the last of the five indicated body regions to be covered in subcutaneous fat, it is likely to have the least amount of fat. A previous study found that scapula muscle thickness was not correlated with ingesta-free body fat (Cook et al. 2007). However, we found that the scapula was the most highly correlated with ingesta-free body fat among all five regions (Table 1). Subcutaneous rump fat is correlated to ingesta-free body fat (Stephenson et al. 2002, Cook et al. 2007). We found scores of the tuber ischium and ilium are similarly correlated to ingesta-free body fat (Table 1). Measurements of depth of back fat were moderately correlated (0.48) to total carcass fat (Anderson et al. 1972). Measurements of subcutaneous fat covering the ribs are not available. We found that scores of the ribs were not highly correlated with ingesta-free body fat.

The VBCIs only provide estimations of body condition when there are some levels of subcutaneous fat present. Body fat in deer is deposited first in bone marrow, then in the abdominal cavity, and finally subcutaneously (Nicholson et al. 1974). Mobilization of fat occurs in the reverse order (Cook et al. 2007). Therefore, a body condition based on subcutaneous fat alone may not be indicative of extremely low nutritional condition as it can only determine whether deer have used all of their subcutaneous fat reserves and not whether they have utilized other fat reserves (Cook et al. 2010). However, the VBCI will reflect if most of the subcutaneous fat reserves are depleted, indicating the deer is in poor condition. Particularly if a deer is in winter range, poor condition will indicate a low chance of survival or successful reproduction (Monteith et al. 2014).

While we found a statistically significant, positive relationship between VBCI and ingesta-free body fat, we encountered issues with video quality, shutter speed, camera angle, and deer coat condition that if addressed may strengthen this relationship. Video quality may explain some of the variation in the VBCI scores. The videos taken in December 2015 had a display resolution of 480p. The videos taken in March 2016 had a display resolution of either 720p or 1080p. In camera trapping studies, maximum resolution is recommended, and 1080p is standard (Fleming, 2014). Evaluating the visibility of the body regions in videos is more difficult with lower resolution, especially when the deer was moving quickly. Shutter speed also affects the visibility of body regions if an animal is moving quickly. Because we recorded videos during their release after capture and handling of the deer, they were usually agitated and running away from the camera. This may have distorted the visibility of the five body regions, potentially making them more or less easily visible than if the deer were stationary or walking. For example, flexion of muscle may have been mistaken for the outline of a bone point, particularly in the scapular region. A higher resolution often requires a slower shutter speed, so a compromise between high resolution and shutter speed will determine the image quality (Rovero et al. 2013). When using camera traps, the deer are less likely to be moving quickly, so resolution should be prioritized.

The condition of the deer's coat also may have affected the variation in the VBCI score (Figure 4). All of the deer in this study had winter coats, which are much thicker than during the summer. The thickness of the coat could have hid or distorted the visibility of any of the five body regions. Also, due to the method of the release of the deer, the coats were sometimes extensively ruffled or wet, which may have distorted the

visibility of the bone points, particularly in the ribcage region. During handling, if an individual was too hot, we would apply water to its coat to cool it down. During the release, a wet coat may have also distorted visibility of the bone regions. It is likely easier to distinguish the visibility of the five body regions when the deer shed their winter coats. However, because mule deer winter range is nutritional limiting (Bishop et al. 2009), winter is the most critical season for deer health to ensure their survival and that they have enough energetic reserves to reproduce. Due to the importance of nutritional condition in winter, the visual body condition indices may be most useful during fall migration to winter range or during winter.

When applying the VBCI several considerations regarding camera placement will improve the number of usable images or videos. Managers should consider the orientation of the deer to the camera. Optimum orientation will take images or videos of the deer walking broadside or quartered to the camera. Broadside images are accomplished more readily if the camera is facing perpendicular to a location where a large number of the study species will cross, such as along a game trail. Particularly with migratory mule deer, camera placement along the migration in an area that funnels the deer will increase the proportion of the population that will be photographed or videoed. The camera should also be placed about three feet from the ground, as this will be an angle that most easily and uniformly will make the five body regions visible.

Future applications of the VBCI will provide new management opportunities that are not feasible with other body condition indices. While other body condition indices exist for large ungulates in North America, the VBCI is both validated and applicable to camera trap images and videos. Using camera traps provides a less expensive and less

potentially harmful method of evaluating deer body condition than traditional methods of estimating body condition. Because capture is not necessary when using the VBCI, the potential for injury or stress to the animal is eliminated. Further, capture of deer is often either extremely time consuming or costly, so application of the VBCI to camera trap images or videos will allow body condition data to become more accessible.

We intend the VBCI to be applied to large samples of mule deer to draw information about the condition of the herd. Management of mule deer often involves improving their habitat to enhance populations. Evaluating body condition of large samples of population can inform management agencies on the effects of these habitat improvements on nutritional availability. Potential applications of the VBCI include evaluating relationships between body condition and habitat enhancements, habitat disturbances, population performances, and weather.

ACKNOWLEDGEMENTS

The UConn IDEA Grant and Office of Undergraduate Research at the University of Connecticut provided funding to support fieldwork for this project. We would like to thank Sarah Reed, University of Connecticut, for initial conversations about visual body condition indices. We would also like to thank volunteers and staff of the Wyoming Game and Fish Department, University of Wyoming, and the Wyoming Cooperative Fish and Wildlife Unit for providing the time and resources required for data collection and laboratory work. We would also like to thank Kayla Hardesty, an undergraduate from the University of Connecticut, and Neil Hymas, a Game Warden with the Wyoming Game and Fish Department, for scoring the videos.

REFERENCES

- Anderson, A.E., E. Medin, and D.C. Bowden. 1972. Indices of Carcass Fat in a Colorado Mule Deer Population. *The Journal of Wildlife Management* 36:579-594.
- Bishop, C. J., G. C. White, D. J. Freddy, B. E. Watkins, and T. R. Stephenson. 2009b. Effect of enhanced nutrition on mule deer population rate of change. *Wildlife Monographs* 172:1-28.
- Bergman, E. J., C.J. Bishop, D.J. Freddy, G.C. White, and P.F. Doherty. 2014. Habitat management influences overwinter survival of mule deer fawns in Colorado. *Journal Wildlife Management* 78:448–455.
- Burton, A. C., E. Neilson, D. Moreira, A. Ladle, R. Steenweg, J.T. Fisher, E. Bayne, and S. Boutin. 2015. REVIEW: Wildlife camera trapping: a review and recommendations for linking surveys to ecological processes. *Journal of Applied Ecology* 52:675–685.
- Cook, R. C., J. G. Cook, D. L. Murray, P. Zager, B. K. Johnson, and M. W. Gratson. 2001. Development of predictive models of nutritional condition for Rocky Mountain elk. *Journal of Wildlife Management* 65:973–987.
- Cook, R. C., T.R. Stephenson, W.L. Myers, J.G. Cook and L.A. Shipley. 2007. Validating Predictive Models of Nutritional Condition for Mule Deer. *Journal of Wildlife Management* 71:1934–1943.

Cook, R. C., Cook, J. G., Stephenson, T. R., Myers, W. L., McCorquodale, S. M., Vales, D. J., Irwin, L. L., Hall, P. B., Spencer, R. D., Murphie, S. L., Schoenecker, K. A. and Miller, P. J. 2010. Revisions of Rump Fat and Body Scoring Indices for Deer, Elk, and Moose. *The Journal of Wildlife Management*, 74: 880–896.

Copeland H.E., H. Sawyer, K.L. Monteith, D.E. Naugle, A. Powewicz, N. Graf, M.J. Kauffman. 2014. Conserving migratory mule deer through the umbrella of sage-grouse. *Ecosphere* 5(9): 1-16.

Gerhart, K. L., R. G. White, R. D. Cameron, and D. E. Russell. 1996. Estimating Fat Content of Caribou from Body Condition Scores. *The Journal of Wildlife Management* 60:713.

Fleming, P., P. Meek, G. Ballard, P. Banks, A. Claridge, J. Sanderson, and D. Swann. 2014. *Camera trapping: wildlife management and research*. Csiro Publishing.

Forrester, T. D. and H. U. Wittmer. 2013. A review of the population dynamics of mule deer and black-tailed deer *Odocoileus hemionus* in North America. *Mammal Review* 43: 292–308.

Johnson, H. E., J.R. Sushinsky, A. Holland, E.J. Bergman, T. Balzer, J. Garner, and S.E. Reed. 2017. Increases in residential and energy development are associated with

- reductions in recruitment for a large ungulate. *Global Change Biology* 23:578–591.
- Kistner, T.P., C.E. Trainer, and N.A. Hartmann, 1980. A Field technique for evaluating physical condition of deer. *Wildlife Society Bulletin* 8:11-17.
- Kucera, T.E. and R.H. Barrett. 2011. A history of camera trapping. *Camera Traps in Animal Ecology*. Springer, New York city, New York, USA.
- Monteith, K. L., V. C. Bleich, T. R. Stephenson, B. M. Pierce, M. M. Conner, G. J. Kie, and R.T. Bowyer. 2014. Life-history characteristics of mule deer: Effects of nutrition in a variable environment. *Wildlife Monographs* 186:1–62.
- Morfeld K. A., J. Lehnhardt, C. Alligood, J. Bolling, J. L. Brown. 2014. Development of a Body Condition Scoring Index for Female African Elephants Validated by Ultrasound Measurements of Subcutaneous Fat. *PLoS ONE* 9(4): e93802.
- Newey, S., P. Davidson, S. Nazir, G. Fairhurst, F. Verdicchio, R.J. Irvine, and R. van der Wal. 2015. Limitations of recreational camera traps for wildlife management and conservation research: a practitioner’s perspective. *Ambio* 44:624-635.
- Nicholson, K. L., W.J. Peterson, W. B. Ballard. 2008. Comparisons and trends in white-tailed deer, *Odocoileus virginianus*, body fat in northeastern Minnesota, 1974-1990. *Canadian Field-Naturalist* 122:253-261.

O'Connell, A. F., J.D. Nichols, and K. U. Karanth. 2010. Camera traps in animal ecology: methods and analyses. Springer Science & Business Media, Japan.

Pérez-Flores, J., S. Calmé, R. Reyna-Hurtado. 2016. Scoring Body Condition in Wild Baird's Tapir (*Tapirus bairdii*) Using Camera Traps and Opportunistic Photographic Material. *Tropical Conservation Science* 9.

Riney, T. 1960. A Field Technique for Assessing Physical Condition of Some Ungulates. *The Journal of Wildlife Management* 24:92-94.

Riney, T. 1982. Study and Management of Large Mammals. New Zealand Sci. Press. Wiley.

Rovero F., F. Zimmermann, D. Berzi, and P. D. Meek. 2013. "Which camera trap type and how many do I need?" A review of camera features and study designs for a range of wildlife research applications. *The Italian Journal of Mammalogy* 24:148-156.

Sawyer, H., M. J. Kauffman, and R. M. Nielson. 2009. Influence of Well Pad Activity on Winter Habitat Selection Patterns of Mule Deer. *The Journal of Wildlife Management* 73: 1052–1061.

Sawyer, H., C. Lebeau. and T. Hart. 2012. Mitigating roadway impacts to migratory mule deer- A case study with underpasses and continuous fencing. *Wildlife Society Bulletin* 36: 492–498.

Stephenson, T. R., K. J. Hundertmark, C. C. Schwartz, and V. Van Ballenberghe. 1998. Predicting body fat and body mass in moose with ultrasonography. *Canadian Journal of Zoology* 76:717–722.

Wright, I. A., and A. J. F. Russell. 1984. Partition of fat, body composition and body condition score in mature cows. *Animal Production* 38:23–32.

TABLES AND FIGURES

Table 1. Spearman's correlation between each body region score using VBCI-1 and scaled IFBF.

* indicates significance ($p < 0.001$)

| Region | Scapula | Rib cage | Spinal ridge | Tuber Ischium | Tuber Ilium | Total |
|---------------|---------|----------|--------------|---------------|-------------|-------|
| IFBF | 0.44* | 0.12 | 0.31* | 0.35* | 0.36* | 0.47* |
| Scapula | -- | 0.35 | 0.42* | 0.38* | 0.47* | 0.80* |
| Rib cage | -- | -- | 0.09 | 0.083 | 0.36* | 0.46* |
| Spinal Ridge | -- | -- | -- | 0.47* | 0.33 | 0.69* |
| Tuber ischium | -- | -- | -- | -- | 0.54* | 0.72* |
| Tuber ilium | -- | -- | -- | -- | -- | 0.76* |

Table 2. Percent agreement between observers using VBCI-1. Observers A and B are the authors of this paper and developers of the VBCI, but have no other prior experience evaluating body condition. Observer C is a volunteer with no prior experience with mule deer or body condition. Observers D and E are considered experts, as they professionally work with and handle mule deer.

| Observer | A | B | C | D | E |
|----------|----|-------|-------|------|-------|
| A | -- | 57.35 | 64.71 | 5.88 | 35.29 |
| B | -- | -- | 80.88 | 4.41 | 22.06 |
| C | -- | -- | -- | 4.41 | 14.71 |
| D | -- | -- | -- | -- | 7.35 |

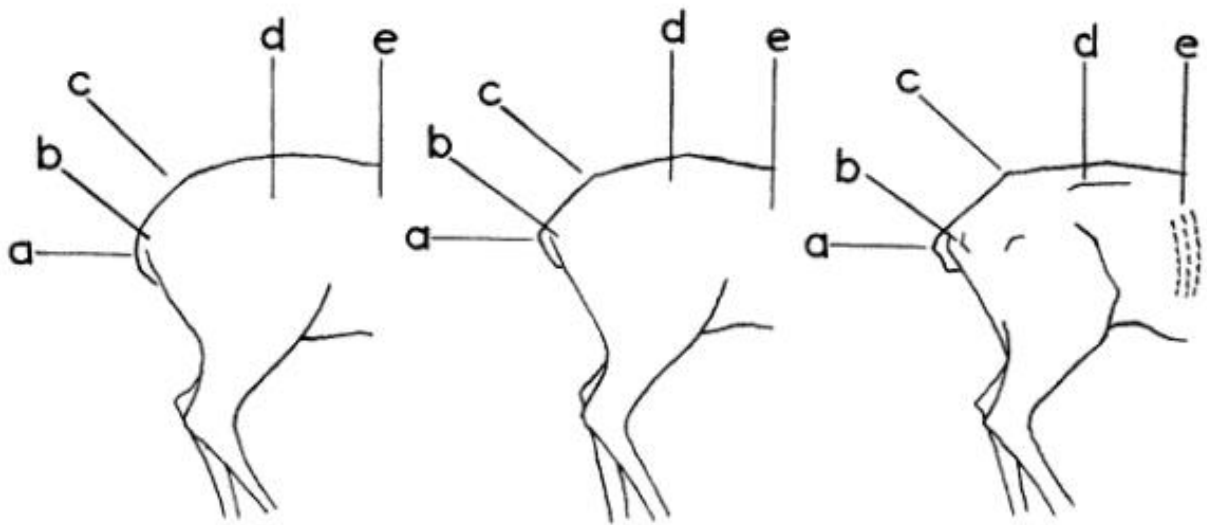



FIG. 1. General appearance of the hind quarters of deer in good, medium, or poor condition.

Figure 1. Visual body condition index developed by Riney (1960). Regions a, b, c, d, and e are used to evaluate body condition visually. These regions are not practical for use with a camera trap because of the difficulty of distinguishing the level of detail needed to determine the visibility of region a, b, and d separately with winter coats.

© The Wildlife Society: Reprinted with permission



VBCI score: 0

1. Scapula visible (0)
2. Spinal ridge visible (0)
3. Ribs visible (0)
4. Tuber ilium visible (0)
5. Tuber ischium visible (0)

VBCI score: 3

1. Scapula somewhat visible (0.5)
2. Spinal ridge not clearly visible (1)
3. Ribs somewhat visible (0.5)
4. Tuber ilium not visible (1)
5. Tuber ischium visible (0)

VBCI score: 5

1. Scapula not visible (1)
2. Spinal ridge not visible (1)
3. No ribs visible (1)
4. Tuber ilium not visible (1)
5. Tuber ischium not visible (1)

Figure 2. Explanation of the Visual Body Condition Index applied to three deer. In this images, region 1 is the scapula, region 2 is the spinal ridge, region 3 is rib cage, region 4 is the tuber ilium, and region 5 is the tuber ischium. This is the ideal body orientation to view all five body regions.

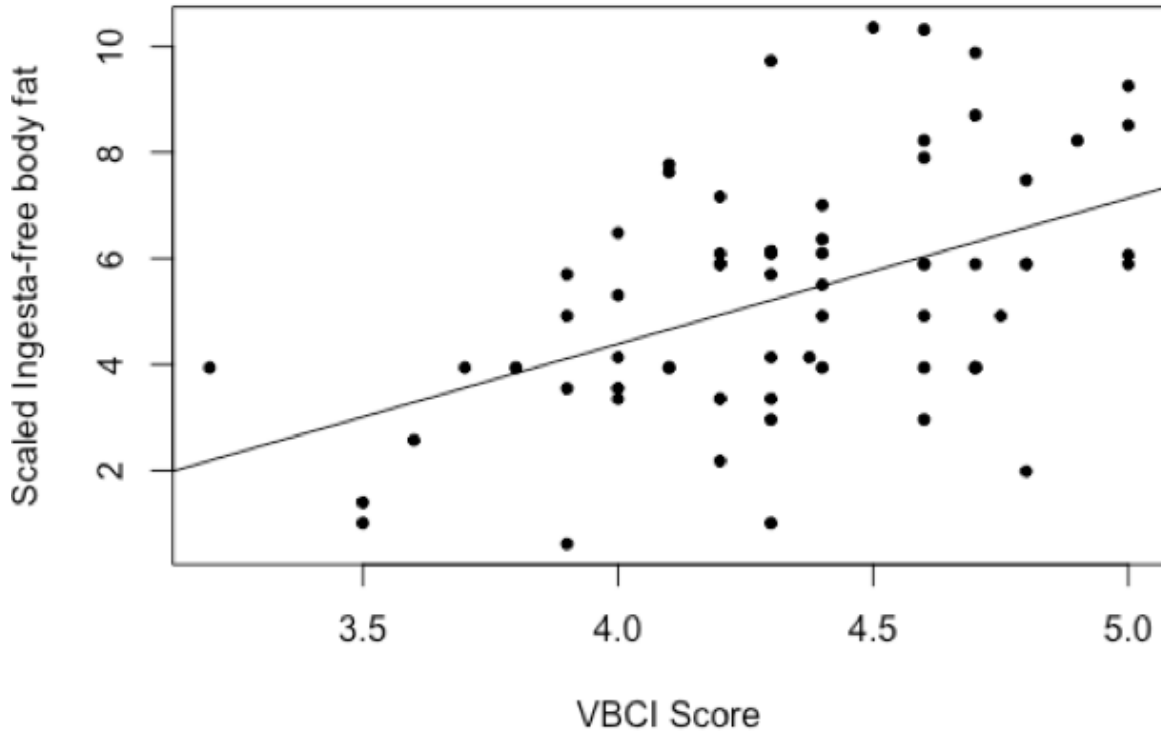


Figure 3. Scatter plot of visual body condition scores using all five body regions (VBCI-1) and measured scaled ingesta-free body fat values in adult female mule deer with a linear model fit ($R^2=0.23$, $p<0.001$). Linear model equation: $y=0.05x+0.41$



Figure 4. An example of a still taken from a release video, showing the ideal camera angle to use VBCI-1. Note the thickness of the winter coat.